

# Radiofrequency Treatment of Genicular Nerves Using a Hybrid Technique

Sandeep Diwan,<sup>1</sup> Anju Gupta,<sup>2</sup> Parag Sancheti<sup>1</sup>

<sup>1</sup>Sancheti hospital Pune, India, <sup>2</sup>Department of Anaesthesiology, Pain Medicine and Critical Care, AIIMS, New Delhi, India.

## ABSTRACT

**Background:** Radiofrequency ablation of genicular nerves is recommended to ameliorate the pain of osteoarthritis of the knee. However, long-term efficacy in patients with persistent pain following total knee arthroplasty remains elusive. The current study aimed to evaluate radiofrequency ablation of genicular nerves using a hybrid technique to manage severe incapacitating pain and quality of life following surgery.

**Methods:** This prospective, observational study included patients suffering from intractable knee pain with scores > 4 on the Numeric rating scale after 6 months of total knee arthroplasty. Therapy included radiofrequency ablation of the superior medial, lateral, and inferior medial genicular nerves using a hybrid technique. The Numeric rating scale and Oxford Knee Score for quality of life were assessed before therapy and at 1-, 3- and 6 months following treatment.

**Results:** Average pain scores reduced from  $8.4 \pm 1.3$  (admission) to  $3.3 \pm 1.4$  (1 month;  $p = <0.001$ ) but subsequently started to increase to  $4 \pm 1.2$  (3 months;  $p = 0.58$ ), and  $5.6 \pm 0.9$  (6 months;  $p = <0.001$ ). Average Oxford Knee Score significantly improved from  $14.2 \pm 5.9$  (admission) to  $38 \pm 8.6$  (1 month);  $p = <0.001$ , but these too subsequently reduced to  $36.4 \pm 7.9$  (3 months);  $p = 1$ , and  $22.5 \pm 12.5$  (6 months);  $p = <0.001$ .

**Conclusions:** Ultrasound-guided radiofrequency ablation of genicular nerves diminishes intractable pain and disability in patients with chronic knee pain following total knee arthroplasty. Treatment is safe and effective, however, the benefit declined by 6 months. A repeat block would be necessary if the pain score worsens.

**Keywords:** Analgesia; arthroplasty; disability; genicular nerve; knee.

## INTRODUCTION

Total knee arthroplasty (TKA) is indicated in severe osteoarthritis to alleviate pain and improve function in elderly patients. Despite a successful surgery, persistent pain can be severe and even worsened.<sup>1,2</sup> Increasing discomfort and immobility leads to consumption of unnecessary analgesics, extensive physiotherapy and the probability of a revision TKA.<sup>3,4</sup>

Percutaneous radiofrequency ablation (RFA) of the genicular nerves (sensory to anterior knee capsule) has been described for treating chronic osteoarthritis-

related knee pain and functional improvement.<sup>5</sup>

Anatomically, genicular nerves have a fixed topographical relation to the femur and tibial condyles, thus, easily accessible with fluoroscopy.<sup>6</sup> However, ultrasound depicts the genicular arteries in relation to the nerves and a combined approach would be more favourable modality for RFA of genicular nerves.

We subjected 21 patients with moderate-to-severe post-TKA anterior knee pain to percutaneous genicular nerve RFA and evaluated NRS and OKS before and immediately after the block at 1, 3 and 6 months.

**Correspondence:** Dr Anju Gupta, Department of Anaesthesiology, Pain Medicine and Critical Care, AIIMS, New Delhi, India. Email: dranjugupta2009@rediffmail.com, Phone: +91991157331.

---

## METHODS

This single-arm prospective observational study was conducted after approval by the Institutional Ethics Committee of a tertiary care centre for Orthopedics and Rehabilitation in India from September 2021 to July 2022 (Ethics Committee Number IEC-SIOR/Agenda 067). Twenty-one eligible patients who had been operated on previously for unilateral or bilateral total knee arthroplasty (TKA) and were incapacitated from chronic pain (>6 months duration) of moderate to severe intensity (numerical Rating Scale (NRS) score of  $\geq 5$ ) refractory to conservative treatments were assessed for eligibility to be recruited for the study. NRS was rated on a scale from 0- to 10-point ranging from none [0] to extreme pain and inability to ambulate [10]. Those willing to participate in the study were recruited to participate in the study.

Patients diagnosed with acute knee pain associated with radicular neuropathy were excluded. Moreover, patients with allergies to local anesthetics, local infection over the knee, systemic sepsis, connective tissue diseases, neurologic or psychiatric disorders with poor ability to comprehend, and those receiving anticoagulant medications qualified for the exclusion.

After obtaining informed consent, the patients received a diagnostic genicular nerve block followed by percutaneous radiofrequency ablation of genicular nerves three weeks after the first block. Based on the anatomical study three genicular branches (nerves and vessels) were identified at the superomedial and superolateral of the shoulder of the femur condyle and inferomedial of the shoulder of the tibial condyle.<sup>7</sup> After aseptic precaution, under a combination of ultrasound and fluoroscopy, 23G spinal needles were positioned and confirmed with fluoroscopy in the anteroposterior and lateral view. One mL mixture of 1% lignocaine and 0.25% bupivacaine was injected at each point and spread visualized in real-time ultrasound. Pain relief was noted on the NRS scale prior to discharge, and if NRS was < 4, patients were counselled for pulsed radiofrequency of genicular nerves.

Under all aseptic precautions, in the supine position, on the operating table, with a pillow underneath the popliteal fossa, the knee was slightly flexed (10-20 degrees). Ultrasound (13-5MHz Fujifilm Sonosite M-turbo) identified the genicular arteries in real time with a longitudinal probe placement along the femur's axis. (Figure 1) Points were marked for needle insertion in approximation with superior medial, lateral and inferior medial genicular arteries for the superior,

medial and lateral genicular nerves. In conjunction with fluoroscopy, a 1% lignocaine was infiltrated deep from within the muscle to the skin at the level of the junction between the shaft of the femur and the medial and lateral condyles. Positioning the introducer cannula close to the periosteum and parallel to the assumed trajectory of the targeted nerve, this same procedure was repeated at the medial tibia to target the inferior medial genicular branch. Needle tip positioning was confirmed by fluoroscopy. (Figure 2)

Subsequently, a pulsed radiofrequency probe [22 G cannula (OWL RF 100mm) with 5 mm active tip electrode; Neuro Therm; Diros Technology Inc; Canada] was advanced through the introducer. A 50Hz sensory stimulation was applied at 0.1 V with increments of 0.1 V with a threshold of < 0.6 V until the patient feels paraesthesia, tingling etc. Additionally, the optimal position of the needles was confirmed by the absence of muscle fasciculations in the corresponding area of the lower extremity at a nerve stimulation of 2 Hz and 1.2 V and an impedance between 300 and 700  $\Omega$ . Two mL lignocaine 1% was injected through each cannula to anesthetize the target nerve and the surrounding tissues. Following these, three lesions for each genicular nerve were created with pulsed radiofrequency treatment performed through the generator [NeuroTherm 100RF generator NeuroTherm, Wilmington, MA, USA] for 90 sec at 20 V to 42°C.<sup>8</sup> Three lesions were created in total, one for each genicular nerve. Patients were continuously monitored for signs of unusual pain and discomfort.

All patients were administered a single injection of paracetamol 1 gm to alleviate procedural pain. After the block, all the patients were prescribed T. pregabalin 75mg HS, T. diclofenac 75mg TDS, T. paracetamol 1gm TDS during the first week followed by diclofenac and paracetamol in the second week and only paracetamol during the third week. Fourth week onwards only paracetamol was prescribed on an as-required basis. If at any time point, a self-assessed NRS was more than 5 despite the above medications, the patient self-administered the tablet tramadol 50mg.

Post-RFA block evaluations were performed with a clinical examination at 1 month, 3- and 6 months by a single independent evaluator who was not the part of investigating team to maintain objectivity. The primary outcomes were the changes from baseline knee pain as measured using the absolute NRS scores and improvement of quality of life (QOL) was evaluated using the Oxford Knee Scale [OKS]. The OKS is a scale that rates the degree of knee pain and the functional

status of the knee and knee-specific QOL on a scale ranging from 0 (worst) to 48 (best score).<sup>9</sup>

The incidence of any adverse events following treatment like abnormal proprioception, numbness, paraesthesia, neuralgia, and motor weakness was recorded.

A total sample size of n=22 was calculated with a repeated measures ANOVA design in mind with an  $\alpha$ -error of 2.5% and 95% power ( $\beta$ -error = 5%) with a medium effect size (f) of 0.25, 1 group to be measured, 5 number of repeated measurements, and a correlation among repeated measures of 0.7. A total sample size of n=25 was decided to tackle attrition rate and possible exclusions due to adverse inpatient events and drop-outs.

The data on categorical variables are shown as n (% of cases) and the data on continuous variables are presented as Mean and Standard deviation (SD). Evaluation of the difference between multiple repeatedly measured means was done using the repeated measures analysis of variance (ANOVA). The underlying assumptions for normality (Shapiro-Wilk) and sphericity (Mauchly) are tested before subjecting the study variables to the ANOVA. Post-hoc tests with the Bonferroni correction are used to evaluate where significant differences lie. All the results are shown in tabular as well as graphical format to visualize statistically significant differences more clearly.

Using the Bonferroni correction for multiple comparisons, p-values less than 0.025 (0.05/2 - for 2 primary outcomes) were considered to be statistically significant. Sample size calculation was done using G\*Power ver. 3.1.9.7 for MS Windows & statistical data analysis was done using JASP ver. 0.16.3 for MS Windows.

## RESULTS

Between September 2021 and July 2022, twenty-eight patients were assessed for eligibility for participation in the study, out of which 25 patients met the inclusion criteria for radiofrequency treatment to relieve the chronic pain caused by TKA. Four patients were lost to follow-up and finally, 21 were analyzed.

The average age of the patients was approximately 73 years and of these, 10 were males and 11 were females. Significant comorbidities affected 18 of 21 patients. These included isolated arterial hypertension (08/21), coronary insufficiency (06/21), and diabetes mellitus type 2 (04/21). None of the patients opted for revision surgery. In all these patients a combination

of gabapentinoids, paracetamol and tramadol and physiotherapy had been unsuccessful in relieving pain prior to the decision for the block procedure.

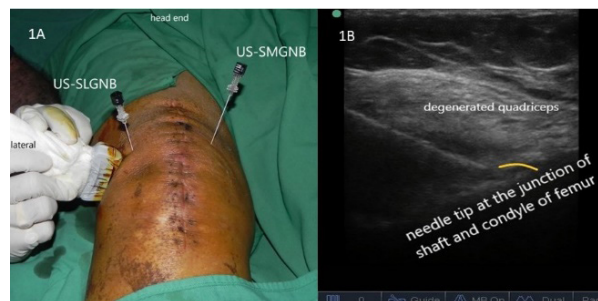The NRS as well as OKS scores improved significantly after the block at 1 month and remained significantly improved than the baseline at 3 and 6 months too. (table- 2)

The baseline mean (SD) Numerical Rating Score (NRS) of the patients was  $8.4 \pm 1.3$  and the mean (SD) Oxford Knee Scores (OKS) were  $14.2 \pm 5.9$  signifying severe pain and functional disability. The mean NRS and OKS scores on admission, and at 1 month, 3 months and 6 months follow-up after PRF ablation of genicular nerves, have been summarized in table 1, figure 3 and figure 4.

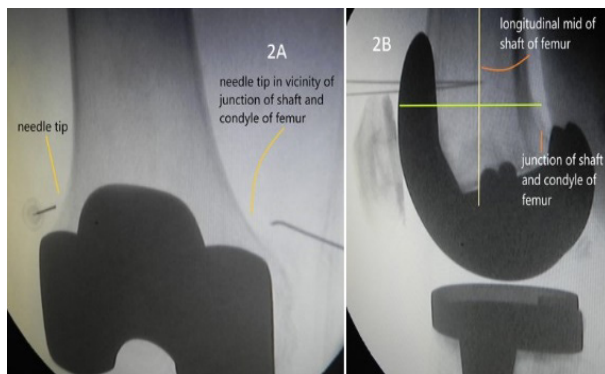
There existed a statistically significant difference between NRS scores in at least 2 different time points on repeated measures ANOVA ( $p < 0.001$ ). On post hoc tests, significant differences were noted between NRS scores on admission and at 1 month, 3 months and 6 months ( $p < 0.001$ ). (Tables 1 & 2)

There existed a statistically significant difference between OKS scores in at least 2 different time points on repeated measures ANOVA ( $p < 0.001$ ). On post-hoc tests, significant differences were noted between OKS scores on admission and at 1 month, 3 months and 6 months ( $p < 0.001$ ) (Tables 1 & 2).

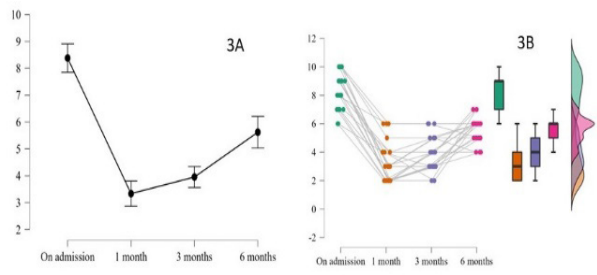
All patients were discharged within a few hours after completion of the procedure. No adverse events were reported until 6 months.



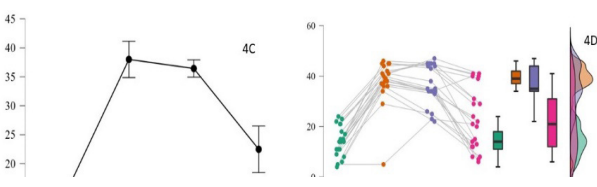
**Figure 1. Ultrasound-guided needle placement for right and left genicular nerve block: 1A-Ultrasound probe placement and needling; 1B-Ultrasound image of genicular nerve block; US-SMGNB: ultrasound-guided superior medial genicular nerve block; US-SLGNB: ultrasound-guided superior lateral genicular nerve block.**



**Figure 2. Confirmation of needle-tip positioning for left and right genicular nerve block using fluoroscopy.**



**Figure 3. A: NRS scores at various time points; B: NRS scores (raincloud).**



**Figure 4. A: OKS scores at various time points; B: OKS scores (raincloud)**

**Table 1. Table 1. NRS and OKS scores .**

	NRS# (mean ± SD)	OKS^ (mean ± SD)
On admission	8.3 ± 1.3	14.2 ± 5.9
1 month	3.3 ± 1.4	38 ± 8.6
3 months	3.9 ± 1.2	36.4 ± 7.8
6 months	5.6 ± 0.9	22.5 ± 12.5

# Numerical Rating Scale

^ Oxford Knee Scale

**Table 2. Comparison of the mean difference [CI] of NRS scores and OKS scores at various time points.**

Baseline Variable	Comparison variable	Mean difference [CI]	P value
<b>NRS# scores</b>			
On admission	1 month	5.0 [4.1 to 5.9]	<.001
	3 months	4.4 [3.4 to 5.3]	<.001
	6 months	2.7 [1.8 to 3.6]	<.001
1 month	3 months	-0.6 [-1.5 to 0.3]	0.58
	6 months	-2.3 [-3.2 to -1.3]	<.001
3 months	6 months	-1.7 [-2.5 to -0.7]	<.001
<b>OKS^ scores</b>			
On admission	1 month	-23.8 [-28.9 to -18.6]	<.001
	3 months	-22.2 [-27.4 to -17]	<.001
	6 months	-8.3 [-13.4 to -3.1]	<.001
1 month	3 months	1.6 [-3.6 to 6.7]	1
	6 months	15.5 [10.4 to 20.7]	<.001
3 months	6 months	13.9 [8.7 to 19.1]	<.001

# Numerical Rating Scale

^ Oxford Knee Scale

**DISCUSSION**

In the present study, the use of RFA of genicular nerves improved the NRS scores and the OKS score at the end of 1 month, 3 months and 6 months following the procedure without any significant adverse effects in patients with persistent pain following TKA. Nonetheless, the benefit declined during the 6-month follow-up period.

Persistent Pain following total knee arthroplasty (PP-TKA) can be diagnosed 3 months after surgical-related pain resolves. At the end of one year, the prevalence could be 13%.<sup>10</sup> However, pain scores might improve after one year.<sup>11</sup> A review mentions that no model predicts the effectiveness of prediction and management strategies for chronic pain after TKA.<sup>12</sup> Interestingly, between fast and slow pain responders, early identification of slow pain responders at 8 weeks will help in providing timely intervention with good outcomes.<sup>13</sup>

Genicular nerve radiofrequency ablation (RFA) is a viable alternative in patients having severe knee pain when increasing doses of analgesics and physiotherapy fail to improve pain scores and when the patient and

---

surgeon prefer to avoid a revision TKA. The genicular nerve block technique involves the blockade of three of the genicular nerves (superolateral, superomedial, and inferomedial) accompanying genicular arteries as they travel around the femur and tibia towards the anterior capsule. The inferolateral genicular nerve is generally omitted because it runs in close proximity to the common peroneal nerve, and its blockade at this site may result in temporary foot drop which can be distressing for the patient. Using fluoroscopic or ultrasound guidance or a hybrid technique as used by us, RFA is performed at the lateral superior, medial superior, and medial inferior genicular nerves, which travel in close proximity to the genicular arteries.

A systemic review depicted a 50-55% reduction in pain for 3 months in the PP-TKA cohort, after PRA of genicular nerves.<sup>14</sup> They described a reduction of pain scores by 3 points amounting to a 55% decrease in PP-TKA in the 3<sup>rd</sup> month after a conventional radiofrequency ablation and the cooled radiofrequency ablation likewise led to a 50% improvement in pain scores. Between conventional, pulsed and cooled radiofrequency there was no difference affecting the pain scores but theoretically, the neuronal damage will be least with the latter two modalities. All the included investigations in the review were individual case reports or small retrospective or prospective case data. With heterogeneity affecting the genicular nerve block for PP-TKA, the application of modality, complications and outcomes could not be established.

Surgical correction and postoperative scarring can lead to the displacement of nerves from their original course. This can pose a risk of injury to the genicular arteries during needle placement.<sup>15</sup> Fluoroscopic-guided genicular nerve ablation is a validated modality as documented in previous studies.<sup>16,17</sup> However, recent literature has shown encouraging results regarding the safety and efficacy of ultrasound-guided genicular nerve blocks. A prospective study did not show any difference in the success and outcomes between fluoroscopic-guided and ultrasound-guided genicular nerve ablation.<sup>18</sup> Impalement of genicular arteries has been mentioned as a concern in literature and a case of hematoma has been previously described following a fluoroscopy-guided genicular nerve block.<sup>15,17</sup> Since the genicular arteries can be visualized using real-time ultrasound, its use adds to the safety of the block.<sup>19</sup> In our study, we confirmed genicular arteries with real-time ultrasound before positioning the needle under fluoroscopic guidance. Thus, the combination of both

modalities added to the procedural safety and we did not witness any adverse effects related to the block till 6 months follow-up in any of our subjects. Previous studies have generally reported the procedure to be safe with only minor complications including pruritus and erythema.<sup>14</sup>

Anatomically, the genicular nerves (superior lateral and superior medial genicular nerves arising from the nerve to vastus lateralis and medialis) innervate the superior lateral and superior medial anterior aspects of the knee capsule. The inferior medial genicular nerve emerges from the sub-patellar branch of the saphenous nerve. The distal portions of the genicular nerves penetrate the knee capsule in the neighbourhood of the junction between the shaft and the condyle.<sup>14</sup> All needles were optimally positioned under fluoroscopy after identifying the genicular arteries with real-time ultrasound. However, it is elusive if the needle tip positions are different in the ablation of genicular nerves in the post-TKA cohort.

We found a mean difference in NRS of 4.4 [3.4 to 5.3] points and a mean difference in OKS of 22.2 [-27.4 to -17] points post-genicular nerve ablation at the end of 3 months. Our study findings are in concordance with the improvement in functional status as reported by previous authors.<sup>14,20</sup>

Though we discerned immediate pain relief after genicular nerve ablation and it persisted for 6 months, however, from the 3<sup>rd</sup> month onwards there was a gradual increase in pain scores requiring analgesics and the probability of the need for second ablation therapy. In PP-TKA cases, pain relief is of good quality for the first 3 months, intermediate from the 3<sup>rd</sup> to 6<sup>th</sup> months. There are reports of pain relief up to 1 year of the procedure.<sup>20</sup>

There are some limitations to our study. Not evaluating the patients until the first year was a key limitation. Moreover, the study had a limited sample size and the data regarding the need for rescue analgesics and the impact of the therapy on patient satisfaction could not be ascertained in our study. The analgesic benefits achieved with the procedure, however, justify exploring this option further in patients with intractable knee pain following the surgery which is hindering their QOL. Not having a control group for comparison is another inherent limitation and further comparative studies of genicular nerve blocks with various conventional therapies can be the direction of future research.



## CONCLUSIONS

Ultrasound-guided radiofrequency ablation of genicular nerves diminishes intractable pain and disability in patients with persistent pain following operated total knee arthroplasty. Treatment is safe and effective, however, the benefit declined by 6 months. A repeat block would be necessary if the pain score worsens.

## CONFLICT OF INTEREST

None

## REFERENCES

1. Wylde V, Hewlett S, Learmonth ID, Dieppe P. Persistent pain after joint replacement: prevalence, sensory qualities, and postoperative determinants. *Pain*. 2011;152:566-72. doi: <https://doi.org/10.1016/j.pain.2010.11.023>
2. Liu SS, Buvanendran A, Rathmell JP, Sawhney M, Bae JJ, Moric M, et al. A cross-sectional survey on prevalence and risk factors for persistent postsurgical pain 1 year after total hip and knee replacement. *Reg Anesth Pain Med*. 2012;37:415-22. doi: <https://doi.org/10.1097/AAP.0b013e318251b688>
3. Van Manen MD, Nace J, Mont MA. Management of primary knee osteoarthritis and indications for total knee arthroplasty for general practitioners. *J Am Osteopath Assoc*. 2012;112:709-15.
4. Singh JA, Vessely MB, Harmsen WS, Schleck CD, Melton LJ 3rd, Kurland RL, et al. A population-based study of trends in the use of total hip and total knee arthroplasty, 1969-2008. *Mayo Clin Proc*. 2010;85:898-904. doi: <https://doi.org/10.4065/mcp.2010.0115>
5. Choi WJ, Hwang SJ, Song JG, Leem JG, Kang YU, Park PH, et al. Radiofrequency treatment relieves chronic knee osteoarthritis pain: a double-blind randomized controlled trial. *Pain*. 2011;152:481-7. doi: <https://doi.org/10.1016/j.pain.2010.09.029>
6. Gardner E. The innervation of the knee joint. *Anat Rec* 1948;101:109-30. doi: <https://doi.org/10.1002/ar.1091010111>
7. Tran J, Peng PWH, Lam K, Baig E, Agur AMR, Gofeld M. Anatomical Study of the Innervation of Anterior Knee Joint Capsule Implication for Image-Guided Intervention. *Reg Anesth Pain Med*. 2018; 43:407-14. doi: <https://doi.org/10.1097/AAP.0000000000000778>
8. Shi W, Rudra R, Vu TN, Gordin Y, Smith R, Kunselman AR. Sensory Stimulation Threshold: A Viable Tool to Improve the Outcome of Lumbar Facet Radiofrequency Denervation? *J Pain Res*. 2021;14:2113-9. doi: <https://doi.org/10.2147/JPR.S319622>
9. Gandek B, Roos EM, Franklin PD, Ware Jr JE. A 12-item short form of the Knee injury and Osteoarthritis Outcome Score (OKS): tests of reliability, validity and responsiveness Osteoarthritis and Cartilage 2019; 27:762-70. doi: <https://doi.org/10.1016/j.joca.2019.01.011>
10. Drosos GI, Triantafilidou T, Ververidis A, Agelopoulou C, Vogiatzaki T, Kazakos K. Persistent post-surgical pain and neuropathic pain after total knee replacement. *World J Orthop*. 2015, 6:528-36. doi: <https://doi.org/10.5312/wjo.v6.i7.528>
11. Phillips JR, Hopwood B, Arthur C, Stroud R, Toms AD: The natural history of pain and neuropathic pain after knee replacement: a prospective cohort study of the point prevalence of pain and neuropathic pain to a minimum three-year follow-up. *Bone Joint J*. 2014, 96:1227-33. doi: <https://doi.org/10.1302/0301-620X.96B9.33756>
12. Beswick AD, Wylde V, Goberman-Hill R. Interventions for the prediction and management of chronic postsurgical pain after total knee replacement: systematic review of randomized controlled trials. *BMJ Open*. 2015, 5:e007387. doi: <https://doi.org/10.1136/bmjopen-2014-007387>
13. Singh JA, Lemay CA, Nobel L, Yang W, Weissman N, Saag KG, et al. Association of Early Postoperative Pain Trajectories with Longer-term Pain Outcome After Primary Total Knee Arthroplasty *JAMA Network Open*. 2019;2(11):e1915105. doi: <https://doi.org/10.1001/jamanetworkopen.2019.15105>
14. Cheppalli N, Bhandarkar A W, Sambandham S, Oloyede SF. Safety and Efficacy of Genicular Nerve Radiofrequency Ablation for Management of Painful Total Knee Replacement: A Systematic Review. *Cureus* 2021;13(11): e19489. doi: <https://doi.org/10.7759/cureus.19489>
15. Strand N, Jorge P, Freeman J, D'Souza RS. A rare

- 
- complication of knee hematoma after genicular nerve radiofrequency ablation. *Pain Rep.* 2019;4:e736. doi: <https://doi.org/10.1097/PR9.0000000000000736>
16. Choi WJ, Hwang SJ, Song JG, Leem JG, Kang YU, Park PH, et al. Radiofrequency treatment relieves chronic knee osteoarthritis pain: a double-blind randomized controlled trial. *Pain.* 2011, 152:481-7. doi: <https://doi.org/10.1016/j.pain.2010.09.029>
17. Kim SY, Le PU, Kosharsky B, Kaye AD, Shaparin N, Downie SA: Is genicular nerve radiofrequency ablation safe? A literature review and anatomical study. *Pain Physician.* 2016, 19:E697-705 .doi: <https://doi.org/10.36076/ppj/2019.19.E679>
18. Kim DH, Lee MS, Lee S, Yoon SH, Shin JW, Choi SS: A prospective randomized comparison of the efficacy of ultrasound- vs fluoroscopy-guided genicular nerve block for chronic knee osteoarthritis. *Pain Physician.* 2019, 22:139-46. doi: <https://doi.org/10.36076/ppj/2019.22.139>
19. Sahoo RK, Krishna C, Kumar M, Nair AS. Genicular nerve block for postoperative pain relief after total knee replacement. *Saudi J Anaesth.* 2020;14 :235-7. doi: [https://doi.org/10.4103/sja.SJA\\_611\\_19](https://doi.org/10.4103/sja.SJA_611_19)
20. Santana Pineda MM, Vanlinthout LE, Moreno Martín A, van Zundert J, Rodriguez Huertas F, Novalbos Ruiz JP. Analgesic effect and functional improvement caused by radiofrequency treatment of genicular nerves in patients with advanced osteoarthritis of the knee until 1 year following treatment. *Reg Anesth Pain Med* 2017;42:62-8. doi: <https://doi.org/10.1097/AAP.0000000000000510>